



Brief Rapid Report

Echocardiographic Findings in Patients With COVID-19 Pneumonia

Hani M. Mahmoud-Elsayed, MD, FESC, FASE, William E. Moody, PhD, MRCP, William M. Bradlow, MRCP, MA, Ayisha M. Khan-Kheil, MRCP, Jonathan Senior, MRCP, Lucy E. Hudsmith, FRCP, DM, and Richard P. Steeds, MD, FRCP, FESC

Department of Cardiology, Queen Elizabeth Hospital Birmingham, University Hospitals Birmingham NHS Foundation Trust, Birmingham, United Kingdom

ABSTRACT

The aim of this study was to characterize the echocardiographic phenotype of patients with COVID-19 pneumonia and its relation to biomarkers. Seventy-four patients (59 ± 13 years old, 78% male) admitted with COVID-19 were included after referral for transthoracic echocardiography as part of routine care. A level 1 British Society of Echocardiography transthoracic echocardiography was used to assess chamber size and function, valvular disease, and likelihood of pulmonary hypertension. The chief abnormalities were right ventricle (RV) dilatation (41%) and RV dysfunction (27%). RV impairment was associated with increased D-dimer and C-reactive protein levels. In contrast, left ventricular function was hyperdynamic or normal in most (89%) patients.

RÉSUMÉ

Cette étude visait à caractériser le phénotype échocardiographique des patients atteints de pneumonie causée par la COVID-19 et sa relation avec des biomarqueurs. Soixante-quatorze patients (âgés de 59 ± 13 ans, 78 % de sexe masculin) hospitalisés en raison de la COVID-19 ont participé à l'étude après leur orientation vers le service de cardiologie pour subir une échocardiographie transthoracique dans le cadre des soins courants. Une échocardiographie transthoracique de niveau 1 de la British Society of Echocardiography a été effectuée en vue d'évaluer la taille et la fonction des cavités cardiaques, la valvulopathie et le risque d'hypertension pulmonaire. Les principales anomalies étaient la dilatation du ventricule droit (41 %) et la dysfonction du ventricule droit (27 %). L'atteinte du ventricule droit était associée à une augmentation des taux de D-dimères et de protéines C-réactives. En revanche, la fonction ventriculaire gauche était hyperdynamique ou normale chez la plupart (89 %) des patients.

In the face of the COVID-19 pandemic, Birmingham has emerged as an epicentre within the United Kingdom. This has led to increasing demand for transthoracic echocardiography (TTE) in critically ill patients being considered for mechanical ventilation and/or circulatory support. Although cardiac biomarkers such as high-sensitivity troponin are emerging as strong predictors of outcome in COVID-19 patients, there are only limited data on echocardiographic findings in these patients. A description of the echocardiographic phenotype and its relation to biomarkers and outcomes is therefore warranted. The aim of this study was to characterize the TTE findings in consecutive patients admitted with proven COVID-19 pneumonia.

Methods

This retrospective observational cohort study included adults 18 years of age or older with COVID-19 pneumonia who underwent TTE between March 22 and April 17, 2020, at a 1215-bed quaternary referral centre. All cases were confirmed through reverse transcriptase polymerase chain reaction assays performed on nasopharyngeal swabs and all patients had pulmonary infiltrates on chest radiograph. Patients were referred for TTE at the discretion of the clinician responsible for the patient's care, with one of the following indications: chest pain, arrhythmia, abnormal electrocardiogram changes, or hemodynamic instability. To minimize the risk of unnecessary exposure to COVID-19 on our echocardiographers, each referral for inpatient TTE was confirmed as appropriate by one of 3 imaging consultant physicians (W.E.M., W.M.B., R.P.S.). Suspected or proven COVID-19 patients proceeded to TTE only after documentation of an elevated high-sensitivity Troponin I (hsTnI) > 14 ng/L, or if unavailable at the time of triage, when urgent assessment was needed to guide escalation or withdrawal of care. During the period of study, departmental echocardiographers were

Received for publication May 4, 2020. Accepted May 24, 2020.

Corresponding author: Dr William E. Moody, Department of Cardiology, Queen Elizabeth Hospital Birmingham, University Hospitals Birmingham NHS Foundation Trust, Nuffield House, Mindelsohn Way, Edgbaston, Birmingham, B15 2TE, United Kingdom. Tel.: +44 (0)7736 275 032.

E-mail: william.moody@nhs.net

See page 1207 for disclosure information.

available 24/7 and to our knowledge, performed all scanning in COVID-19 patients to the exclusion of other point of care ultrasound examinations. Patients with previously abnormal echocardiography ($n = 3$) were excluded from the analysis, with the aim of isolating as far as possible abnormalities due to COVID-19.

Echocardiography was performed (Sparq 795090CC ultrasound system, Philips Healthcare, Amsterdam, Netherlands) using a phased array S5 probe by experienced, accredited echocardiographers (level 2 proficiency accreditation British Society of Echocardiography [BSE]) following a modified level 1 focused protocol with assessment of chamber size and function, valvular disease, and likelihood of pulmonary hypertension.¹ The BSE level 1 protocol does not require measurements to be performed and does not include tissue Doppler.

Measurements were performed retrospectively, offline using the archived images by 2 independent observers (H.M.M.-E. and J.S.) blinded to the clinical data, in accordance with the 2015 joint guidelines from the American Society of Echocardiography and the European Association of Cardiovascular Imaging.² The right ventricle (RV) was assessed in an appropriately focused view. The RV was defined as dilated if the RV basal diameter measured > 41 mm; RV systolic dysfunction was defined as a fractional area change $< 35\%$ or a tricuspid annular plane systolic excursion < 17 mm. The echocardiographic probability of pulmonary hypertension was assessed in accordance with European Association of Cardiovascular Imaging guidelines.³ Left ventricular (LV) systolic function was assessed visually, as per the BSE level 1 guidance.¹

All patients underwent routine chest radiography. Computed tomography pulmonary angiography was performed in selected cases at the discretion of the clinical team.

Data were manually extracted from electronic health records. For patients with COVID-19 disease, the need for individual consent was waived by national United Kingdom guidance covering research during the COVID-19 pandemic because the data were collected by members of usual clinical care teams for the primary purposes of clinical need and/or locally approved service evaluation. This study was reviewed and approved by the University Hospitals Birmingham NHS Foundation Trust COVID-19 Related Research and Audit Board.

Results

Baseline demographic characteristics, risk factors, and clinical, laboratory, and echocardiographic characteristics are presented in [Table 1](#). The mean age was 59 ± 13 years, 78% were male, and 72% white. Most patients had severe type 1 respiratory failure (partial pressure of oxygen < 8 kPa or < 60 mm Hg) requiring mechanical ventilation (82%), with more than half (58%) requiring vasopressor support (norepinephrine) during admission.

The median time between admission and echocardiography was 5 days (interquartile range [IQR], 3-10 days). LV systolic function was hyperdynamic or normal in most cases (89%), the RV was dilated in 41%, and impaired in 27%. RV systolic dysfunction was associated with pulmonary embolism (20%). The median time between echocardiography and the


peak levels of D-dimer, C-reactive protein (CRP), and hsTnI was 3 days (IQR, 1-5 days). RV systolic dysfunction (defined by fractional area change) was significantly associated with elevated D-dimer ($\rho = -0.34$; $P = 0.003$) and CRP ($r = -0.23$; $P = 0.045$) but was not related to hsTnI ([Fig. 1](#)). RV size and function was not related to use of vasopressors or mechanical ventilation. Patients with RV dysfunction during mechanical ventilation had lower mean ratio of arterial oxygen concentration in mm Hg to the fraction of inspired oxygen (a marker of acute respiratory distress syndrome severity), and higher mean fraction of inspired oxygen and positive end-expiratory pressure, although results did not meet statistical significance. No patient had more than mild regurgitation and none had any degree of valvular stenosis.

Twenty-three patients (31%) underwent repeat echocardiography after a median interval of 8 days (IQR, 3-20 days). Across the cohort, there were no significant differences in LV or RV size and function compared with the baseline study.

At the time of submission, 28 patients (38%) had died, of whom 14 (41%) had a RV abnormality (13 dilated, 7 impaired), whereas only 2 (7%) had LV impairment. To date, 15 (20%) have been discharged.

Discussion

In patients with COVID-19 pneumonia, RV dilatation and dysfunction is common and its presence is associated with a prothrombotic, inflammatory state reflected in elevated D-dimer and CRP levels. In contrast, LV size is normal and LV function is hyperdynamic in most, whereas significant valvular abnormalities, either primary or secondary, are absent.

Visual RV assessment has highlighted many subjects with marked reduction in radial RV systolic function but relative preservation of longitudinal shortening. This likely explains the discrepancy between the objective tricuspid annular plane systolic excursion and FAC measurements among patients with reduced RV function. Indeed, many patients exhibited the McConnell sign (exemplar case, see [Video 1](#)  view video online), which involves severe free wall hypokinesia or akinesia with apical sparing. This sign is not specific for acute pulmonary embolus (especially in patients receiving mechanical ventilation) and we believe in most COVID-19 patients this could instead represent acute cor pulmonale secondary to acute respiratory distress syndrome. Although this study has not shown a link between mechanical ventilation and the presence of RV dysfunction and pulmonary hypertension, identification of RV impairment might prompt physicians to limit positive end-expiratory pressure and avoid hypercapnic acidosis, which could otherwise adversely affect RV performance by inducing pulmonary arteriolar vasoconstriction and increased RV afterload.

Echocardiography might also be used to help identify which patients with COVID-19 could benefit from therapeutic anticoagulation; although there is no current consensus, it was used empirically to good effect in Wuhan patients with very high D-dimer levels.⁴ Prospective randomized trials might be warranted to determine whether TTE-guided systemic anticoagulation confers survival benefit in hospitalized patients with COVID-19.⁵ Acute myocarditis causing severe LV dysfunction has also been reported in COVID-19 patients,⁶ but on the basis of our cohort, there is a

Table 1. Baseline demographic characteristics, risk factors, and laboratory, clinical, and echocardiographic characteristics (N = 74)

Variable	All patients (N = 74)	Normal right ventricular systolic function (n = 54)	Impaired right ventricular systolic function (n = 20)	P
Baseline demographic characteristics and risk factors				
Age, years	59 ± 13	59 ± 13	58 ± 13	0.73
Sex				0.27
Male	58 (78)	40 (74)	18 (90)	
Female	16 (22)	14 (26)	2 (10)	
Ethnicity				0.68
White	46 (62)	33 (61)	13 (65)	
Asian	26 (35)	19 (35)	7 (35)	
Afro-Caribbean	2 (3)	2 (4)	0 (0)	
Hypertension	31 (42)	24 (44)	7 (35)	0.47
Diabetes mellitus	27 (36)	18 (33)	9 (45)	0.36
Chronic kidney disease	8 (11)	8 (15)	0 (0)	0.10
Stroke	5 (7)	5 (9)	0 (0)	0.31
Current smoker	5 (7)	5 (9)	0 (0)	0.32
Lung disease	10 (14)	7 (13)	3 (15)	1.00
Coronary artery disease	7 (9)	7 (13)	0 (0)	0.18
History of malignancy	5 (7)	4 (7)	1 (5)	1.00
Laboratory findings				
Full blood count				
Hemoglobin, g/L	128 ± 24	127 ± 23	133 ± 26	0.35
Platelets, n/mm ³	226 (172-287)	218 (170-280)	243 (184-315)	0.34
White cell count, n/mm ³	9 (7-13)	8.5 (6-12)	11.2 (8-15)	0.04
Neutrophils, n/mm ³	7.4 (5.2-11.6)	7 (4.8-11.2)	9.5 (6.4-12.4)	0.07
Lymphocytes, n/mm ³	0.97 ± 0.53	0.94 ± 0.55	1.1 ± 0.49	0.37
Neutrophil to lymphocyte ratio	9.0 (5.2-16.6)	8.2 (4.5-16.6)	11.2 (6.3-16.5)	0.46
hs-Troponin I, ng/L	14 (6-67)	15 (6-64)	12 (6-252)	0.19
D-dimer, ng/L	657 (365-2066)	635 (365-1396)	724 (410-6362)	0.33
C-reactive protein, mg/dL	307 ± 114	298 ± 112	328 ± 119	0.19
Chest radiograph findings				
Bilateral pulmonary infiltrates	74 (100)	54 (100)	20 (100)	1.0
Ventilatory parameters*				
Mechanical ventilation at time of echocardiogram	58 (78)	42 (78)	16 (80)	0.84
Fraction of inspired oxygen	0.57 ± 0.17	0.55 ± 0.17	0.62 ± 0.19	0.17
PO ₂ /FiO ₂	142 ± 44	142 ± 41	139 ± 52	0.80
Positive end-expiratory pressure, cm H ₂ O	9.3 ± 2.9	9.1 ± 3.2	9.8 ± 2.2	0.46
Echocardiographic parameters				
Left ventricular size				
End-diastolic dimension, mm	42 ± 8	42 ± 7	40 ± 10	0.40
Small	15 (20)	8 (15)	7 (35)	0.14
Normal	56 (76)	44 (82)	12 (60)	
Dilated	3 (4)	2 (4)	1 (4)	
Left ventricular systolic function, visual assessment				
Hyperdynamic	36 (48)	23 (43)	13 (65)	0.35
Normal	30 (41)	25 (46)	5 (25)	
Mildly impaired	4 (5)	3 (6)	1 (5)	
Moderately impaired	2 (3)	1 (2)	1 (5)	
Severely impaired	2 (3)	2 (4)	0 (0)	
Right ventricular size				
Normal	44 (59)	40 (74)	4 (20)	< 0.0001
Dilated	30 (41)	14 (26)	16 (80)	
RV basal diameter, mm	40 (35-44)	39 (34-43)	44 (40-49)	0.004
Right ventricular systolic function				
Normal	54 (73)	-	-	-
Impaired	20 (27)	-	-	-
TAPSE, mm	23 ± 5	23 ± 4	21 ± 6	0.17
Fractional area change, %	40 (34-45)	40 (37-50)	30 (30-34)	< 0.001
Peak TR velocity, m/s [†]	2.9 ± 0.6	2.9 ± 0.7	2.8 ± 0.4	0.75
Pulmonary hypertension				
Low probability	12 (16)	12 (22)	0 (0)	0.006
Intermediate probability	13 (18)	5 (9)	8 (40)	
High probability	12 (16)	9 (17)	3 (15)	
Unable to estimate [‡]	37 (50)	28 (52)	9 (45)	
Pericardial effusion	3 (4)	3 (6)	0 (0)	0.56
During hospital stay				
Vasopressor support	43 (58)	31 (57)	12 (60)	0.84
Invasive mechanical ventilation	61 (82)	45 (83)	16 (80)	0.74

Continued

Table 1. Continued.

Variable	All patients (N = 74)	Normal right ventricular systolic function (n = 54)	Impaired right ventricular systolic function (n = 20)	P
Pulmonary embolism [§]	5 (7)	1 (2)	4 (20)	0.02
Death	28 (38)	21 (39)	7 (35)	-

Data are presented as n (%), mean ± SD, or median (interquartile range). The normality of distribution for continuous variables was determined using the Kolmogorov–Smirnov test. Variables not normally distributed were log-transformed. Baseline data were analyzed using independent samples Student *t*, χ^2 , or where appropriate, Fisher exact tests.

CT, computed tomography; hs, high-sensitivity; PO2/FiO2 (also known as the Horowitz or P/F ratio), the ratio of arterial oxygen concentration in mm Hg to the fraction of inspired oxygen; RV, right ventricle; TAPSE, tricuspid annular plane systolic excursion; TR, tricuspid regurgitation.

* In the 58 patients with mechanical ventilation at the time of the echocardiogram.

† In the 37 patients with a measurable tricuspid regurgitation continuous wave Doppler signal.

‡ Due to an incomplete tricuspid regurgitation continuous wave Doppler signal.

§ Diagnosis made using CT pulmonary angiography. CT pulmonary angiography was performed in 20 of the 74 patients (27%).

low prevalence of LV impairment despite the ubiquitous presence of bilateral lung infiltrates on chest radiograph.

There are limitations to this study. As a retrospective observational cohort study, it is inevitably subject to selection bias. TTE was restricted to patients with COVID-19 pneumonia with elevated HS Tn for safety reasons; these findings are not, therefore, generalizable to the many asymptomatic or paucisymptomatic individuals with COVID-19. Furthermore,

only patients with positive reverse transcriptase polymerase chain reaction assays for COVID-19 were included and we acknowledge that the limited sensitivity of this assay (approximately 70%) means that patients with false negative nasopharyngeal swab results who underwent echocardiography were excluded. We acknowledge that echocardiographic estimation of pulmonary hypertension is challenging in critically ill patients and the studies that validated this approach

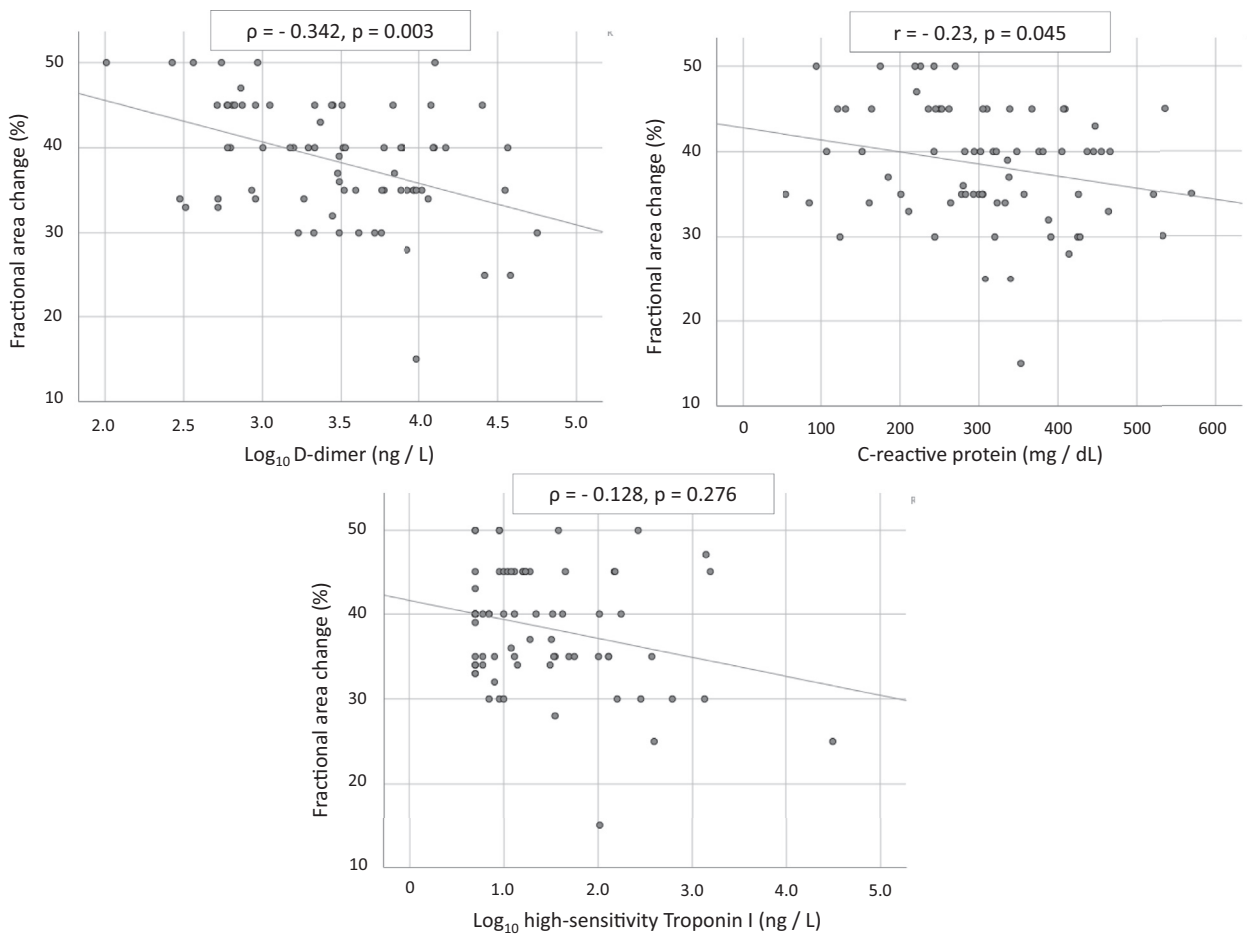


Figure 1. Relationship between biomarkers and right ventricular systolic function. Pearson correlation was used for normally distributed data, and Spearman rank correlation for data not normally distributed; a 2-tailed *P* < 0.05 was considered significant.

did not include patients receiving mechanical ventilation; however, TTE was performed according to current appropriate guidelines. Finally, not all of the patients underwent computed tomography pulmonary angiography and it is conceivable, therefore, that a proportion of patients with RV dysfunction had undiagnosed thromboembolic disease.

In conclusion, RV dilatation and dysfunction is common in patients with COVID-19 pneumonia and elevated HS Tn. In contrast, the left ventricle is seldom impaired and more often hyperdynamic.

Funding Sources

The authors have no funding sources to declare.

Disclosures

The authors have no conflicts of interest to disclose.

References

1. Hindocha R, Garry D, Short N, et al. Minimum dataset for a level 1 echocardiogram: a guideline protocol from the British Society of Echocardiography. *Echo Res Prac* 2020;7:G51-8.
2. Lang RM, Badano LP, Mor-Avi V, et al. Recommendations for cardiac chamber quantification by echocardiography in adults: an update from the American Society of Echocardiography and the European Association of Cardiovascular Imaging. *J Am Soc Echocardiogr* 2015;28:1-39.e14.
3. Galìè N, Humbert M, Vachiery JL, et al. 2015 ESC/ERS guidelines for the diagnosis and treatment of pulmonary hypertension: the Joint Task Force for the Diagnosis and Treatment of Pulmonary Hypertension of the European Society of Cardiology (ESC) and the European Respiratory Society (ERS): Endorsed by: Association for European Paediatric and Congenital Cardiology (AEPC), International Society for Heart and Lung Transplantation (ISHLT). *Eur Heart J* 2016;37:67-119.
4. Tang N, Bai H, Chen X, et al. Anticoagulant treatment is associated with decreased mortality in severe coronavirus disease 2019 patients with coagulopathy. *J Thromb Haemost* 2020;18:1094-9.
5. Paranjpe I, Fuster V, Lala A, et al. Association of treatment dose anti-coagulation with in-hospital survival among hospitalized patients with COVID-19. *J Am Coll Cardiol* 2020;76:122-4.
6. Inciardi RM, Lupi L, Zaccone G, et al. Cardiac involvement in a patient with coronavirus disease 2019 (COVID-19) [e-pub ahead of print]. *JAMA Cardiol* <https://doi.org/10.1001/jamacardio.2020.1096>.

Supplementary Material

To access the supplementary material accompanying this article, visit the online version of the *Canadian Journal of Cardiology* at www.onlinecjc.ca and at <https://doi.org/10.1016/j.cjca.2020.05.030>.